

Correspondence

Side Effects of Pyrethroid and Supporting Role of Onion in the Male Rat's Spermatogenesis

Arash Khaki¹, Asghar Rajabzadeh², Amir Afshin Khaki³

¹Department of Pathology, Tabriz Branch, Islamic Azad University, Tabriz, Iran

²Department of Anatomical Science, Faculty of Medicine, Tabriz University of Medical Sciences, Tabriz, Iran

³Department of Anatomical Science, Women's Reproductive Health Research Center, Tabriz University of Medical Sciences, Tabriz, Iran

To the Editor: Permethrin is a great handmade of chemical agents, pyrethroid Type I, which exists in two main isomers, Cis and Trans.^[1] Its application in farming and building is due to well availability and repelling of pests. It may be easy absorbed from the gastrointestinal and skin tract and by inhalation of dust.^[2,3] They are great chemicals with high producing of reactive oxygen species and inducer of necrosis pathway. Inadequate information of using permethrin resulted in many side effects on biological systems. Spermatogenesis is one of the main vital systems susceptible to reactive oxygen species and oxidative stress.^[4] Since spermatogenesis takes place in the testis, any chemical agent like permethrin could be destroyed cellular structure and function and leads to infertility.^[5] On the other hand, done studies for confronting these effects were mostly focused

on reducing infertility rate and proposing the best way to treatment. Most studies represent a varied range of antioxidants to solving male infertility. *Allium cepa* (onion), a natural antioxidant, was used in traditional medicine. It protects DNA and other important molecules from oxidative stress and improves sperm parameters, so leads to increase fertility rate.^[6]

The thirty male rats, weighing 250 ± 10 g, were randomly divided into three groups. Group 1 (control) was only under normal conditions of food and water. Group 2 received permethrin ($35 \text{ mg} \cdot \text{kg}^{-1} \cdot \text{d}^{-1}$) orally, dissolved in 0.5 ml/kg DMSO. $1/100$ of the LD50 value of permethrin was chosen based on the "no observed adverse effect level" for permethrin.^[7] At the same dose of permethrin, Group 3 was also treated with onion juice (3 ml/d).

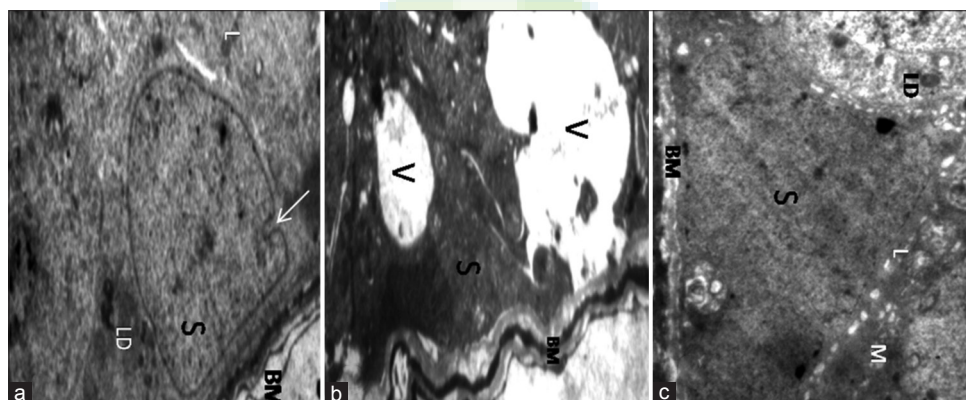


Figure 1: Transmission electron micrograph images of Sertoli cells. (a) Control group. Sertoli cell (S) with regular euchromatic nuclei resting on a regular BM. Also LD, lysosomes (L) can be seen (original magnification $\times 6000$). (b) Permethrin group. Sertoli cell with irregular nucleus (S) and BM. There are large vacuoles (V) in the cytoplasm (original magnification $\times 6000$). (c) Permethrin-onion group. Sertoli cell with regular euchromatic nuclei and prominent nucleolus (S), decreased number of vacuoles compared with Permethrin group. LD (original magnification $\times 6000$). BM: Basement membrane; LD: Lipid droplets.

The electron-graph of images of control group showed that Sertoli cells rested on a thin regular basement membrane, and having clear border, euchromatic nuclei and normal cytoplasmic organelles (secretary granules and mitochondria). The Sertoli cell nuclei of permethrin group exhibited heterochromatin and irregular

Address for correspondence: Dr. Arash Khaki,
Department of Pathology, Tabriz Branch, Islamic Azad
University, Tabriz, Iran
E-Mail: Khaki@iaut.ac.ir

Access this article online

Quick Response Code:



Website:
www.cmj.org

DOI:
10.4103/0366-6999.220297

This is an open access article distributed under the terms of the Creative Commons Attribution-NonCommercial-ShareAlike 3.0 License, which allows others to remix, tweak, and build upon the work non-commercially, as long as the author is credited and the new creations are licensed under the identical terms.

© 2017 Chinese Medical Journal | Produced by Wolters Kluwer - Medknow

Received: 19-07-2017 **Edited by:** Yi Cui

How to cite this article: Khaki A, Rajabzadeh A, Khaki AA. Side Effects of Pyrethroid and Supporting Role of Onion in the Male Rat's Spermatogenesis. Chin Med J 2017;130:3015-6.

shape, great vacuoles spaces in the cytoplasm. There were spaces between the basement membrane and Sertoli cells. These cells in the permethrin-onion group represented a typical triangular and euchromatic nucleus adjacent to a regular-thin basement membrane [Figure 1].

Environmental toxicants induced cellular and hormonal damages by variety pathways. Many studies have been carried out concerning the effects of pesticides compounds on male infertility. Previously, it has been reported that oxidative stress is a cause of permethrin exposure.^[8-10] The electron microscope examination revealed that permethrin exposure caused to prominent histomorphometric alterations including vacuolization of Sertoli, and disorganization of the basement membrane. Nowadays, natural antioxidants are used worldwide to decrease harmful effects of environmental pollutants. The results indicated an overall improvement of permethrin-induced alterations on coadministration of onion juice.

Exposure to insecticides (permethrin) induced testicular damages, which exhibits with histological alterations in adult male testes. Furthermore, administration of onion juice is associated with decreasing the toxic effects of permethrin. Thus, onion juice could maintain reproductive ability and improves sexual activities. However, the effective strategy to men infertility is avoiding using of insecticides.

Financial support and sponsorship

Nil.

Conflicts of interest

There are no conflicts of interest.

REFERENCES

1. Papadopoulou-Mourkidou E. Analysis of established pyrethroid insecticides. *Residue Rev* 1983;89:179-208. doi: 10.1007/978-1-4612-5601-4_3.
2. Fonger GC, Hakkinen P, Jordan S, Publicker S. The National Library of Medicine's (NLM) Hazardous Substances Data Bank (HSDB): background, recent enhancements and future plans. *Toxicology*. 2014;325:209-16. doi: 10.1016/j.tox.2014.09.003.
3. Bradberry SM, Cage SA, Proudfoot AT, Vale JA. Poisoning due to pyrethroids. *Toxicol Rev* 2005;24:93-106. doi: 10.2165/00139709-200524020-00003.
4. Hemadi M, Saki G, Rajabzadeh A, Khodadadi A, Sarkaki A. The effects of honey and Vitamin E administration on apoptosis in testes of rat exposed to noise stress. *J Hum Reprod Sci* 2013;6:54-8. doi: 10.4103/0974-1208.112383.
5. Khaki A, Khaki AA, Rajabzadeh A. The effects of Permethrin and antioxidants properties of *Allium cepa* on testicles parameters of male rats. *Toxin Rev* 2017;36:1-6. doi: 10.1080/15569543.2016.1235582.
6. Khaki A, Farnam A, Badie AD, Nikniaz H. Treatment effects of onion (*Allium cepa*) and ginger (*Zingiber officinale*) on sexual behavior of rat after inducing an antiepileptic drug (lamotrigine). *Balkan Med J* 2012;29:236-42. doi: 10.5152/balkanmedj.2012.045.
7. Parkinson GR. Permethrin: Acute toxicity to male rats. Imperial Chemical Industries Ltd.; 1978. p. 388.
8. Gabbianelli R, Nasuti C, Falcioni G, Cantalamessa F. Lymphocyte DNA damage in rats exposed to pyrethroids: Effect of supplementation with Vitamins E and C. *Toxicology* 2004;203:17-26. doi: 10.1016/j.tox.2004.05.012.
9. Otitoju O, Onwurah IN, Otitoju GT, Ugwu CE. Oxidative stress and superoxide dismutase activity in brain of rats fed with diet containing Permethrin. *Biokemistri* 2008;20:93-8.
10. Sharma P, Huq AU, Singh R. Cypermethrin-induced reproductive toxicity in the rat is prevented by resveratrol. *J Hum Reprod Sci* 2014;7:99-106. doi: 10.4103/0974-1208.138867.

