

**Effect of non-ionizing electromagnetic field on the alteration of ovarian follicles in rats**Seyed Shahin Ahmadi<sup>1</sup>, Amir Afshin Khaki<sup>2</sup>, Nava Ainehchi<sup>3</sup>, Alireza Alihemmati<sup>4</sup>, Azam Asghari Khatoooni<sup>5</sup>, Arash Khaki<sup>6</sup>, Ali Asghari<sup>7</sup>

<sup>1</sup> Ph.D. Student of Histology & Embryology, Tabriz Health Services Management Research Center, Tabriz University of Medical Sciences, Tabriz, Iran

<sup>2</sup> Ph.D. of Anatomy, Associate Professor, Tabriz Health Services Management Research Center, Tabriz University of Medical Sciences, Tabriz, Iran

<sup>3</sup> Ph.D. Student, Women's Reproductive Health Research Center, Tabriz University of Medical Sciences, Tabriz, Iran

<sup>4</sup> Ph.D. of Histology & Embryology, Associate Professor, Department of Anatomical sciences, Tabriz University of Medical Sciences, Tabriz, Iran

<sup>5</sup> M.Sc. of Midwifery, Alzahra Hospital, Tabriz University of Medical Sciences, Tabriz, Iran

<sup>6</sup> Ph.D. of Pathology, Associate Professor, Women's Reproductive Health Research Center, Tabriz University of Medical Sciences, Tabriz, Iran

<sup>7</sup> M.Sc. of Anatomy, Department of Anatomy, Faculty of Medicine, Tabriz University of Medical Sciences, Tabriz, Iran

**Type of article:** Original

**Abstract**

**Introduction:** In recent years, there has been an increase in the attention paid to safety effects, environmental and society's health, extremely low frequency electromagnetic fields (ELF-EMF), and radio frequency electromagnetic fields (RF-EMF). The aim of this research was to determine the effect of EMF on the alteration of ovarian follicles.

**Methods:** In this experimental study at Tabriz Medical University in 2015, we did EMF exposures and assessed the alteration of rats' ovarian follicles. Thirty three-month old rats were selected randomly from laboratory animals, and, after their ages and weights were determined, they were divided randomly into three groups. The control group consisted of 10 rats without any treatment, and they were kept in normal conditions. The second group of rats was influenced by a magnetic field of 50 Hz for eight weeks (three weeks intrauterine and five weeks ectopic). The third group of rats was influenced by a magnetic field of 50 Hz for 13 weeks (three weeks intrauterine and ten weeks ectopic). Samples were fixed in 10% buffered formaldehyde and cleared with Xylool and embedded in paraffin. After sectioning and staining, samples were studied by optic microscopy. Finally, SPSS version 17, were used for data analysis.

**Results:** EMF radiation increased the harmful effects on the formation of ovarian follicles and oocytes implantation. Studies on the effects of electromagnetic fields on ovarian follicles have shown that the nuclei of the oocytes become smaller and change shape. There were significant, harmful changes in the groups affected by electromagnetic waves. Atresia of ovarian follicles was significantly significant in both study groups compared to the control group ( $p < 0.05$ ).

**Conclusion:** Exposure to electromagnetic fields during embryonic development can cause morphological changes in oocytes and affect the differentiation of oocytes and folliculogenesis, resulting in decreased ovarian reserve leading to infertility or reduced fertility.

**Keywords:** electromagnetic field, follicle, rats, infertility

**1. Introduction**

Human progress in the field of new technologies in the field of health has implications that require management and some health interventions. Recently, interest has increased in electromagnetic fields due to concerns about the

**Corresponding author:**

Associate Professor Dr. Amir Afshin Khaki, Tabriz Health Services Management Research Center, Tabriz University of Medical Sciences, Tabriz, Iran. Tel: +98.9144157161, Email: [dr.aakhaki@yahoo.com](mailto:dr.aakhaki@yahoo.com)

Received: January 04, 2016, Accepted: March 03, 2016, Published: March 2016

iThenticate screening: March 03, 2016, English editing: March 08, 2016, Quality control: March 12, 2016

© 2016 The Authors. This is an open access article under the terms of the Creative Commons Attribution-NonCommercial-NoDerivs License, which permits use and distribution in any medium, provided the original work is properly cited, the use is non-commercial and no modifications or adaptations are made.

potential effects of EMF, both on human health and animals (1, 2). We live in a world that is completely surrounded by the Earth's geomagnetic field with 0.5Oe and electromagnetic pollution is caused by man-made sources. The damaging effects of electromagnetic fields depend on the frequency (wavelength), the density of the field, and the duration of radiation (1). Extremely low frequency electromagnetic fields (ELF-EMF), non-ionizing radiation that has a frequency range in home appliances with frequency of 50 or 60 Hz that emit waves with long wavelength (3). Most electrical appliances work in the frequency range between 50 and 60 Hz, and further studies of the impact of electromagnetic radiation on living organisms is being done in this frequency range. Fifty Hertz corresponds to a wavelength of 3,500 kilometers, which is close to the Earth's radius (3). Many studies have been conducted to determine the possible effects of low frequency fields on human health (4-6). It seems that electromagnetic fields can cause infertility in women (7, 8). ELF-EMF has devastating effects on the reproductive system of female rats, e.g., it reduces the number of flushed blastocysts and increases the height of the epithelial cells in the fallopian tubes (9). ELF-EMF radiation can cause changes in the uterus and ovaries in rats (10), influence follicular development, influence the estrus cycle, and cause birth defects, miscarriage, and premature birth (11). The development of tissues, organs, and systems during embryogenesis is sensitive to toxic agents (10). EM fields potentially can affect fetal development, but their mechanisms still are not fully understood (12). Based on available studies of human subjects, exposure to electromagnetic fields (parental exposure) with frequencies from 50 to 60 Hz both before and during pregnancy can have an important role in the development of childhood cancer (13). It also has been shown that exposure to extremely low frequency electromagnetic fields during pregnancy can cause adverse effects in pregnant female rats and the development of their newborns. Abortion, fetal loss, malformation, and growth delay in the offspring of pregnant rats are some of the effects of EMF (10). Because of their jobs, physiotherapists who are pregnant are affected by microwave radiation, they have an increased risk of miscarriage. Living in proximity (closer than 50 meters) of an ELF-EMF source during pregnancy can cause suboptimal growth of the uterus (14). Another study also found that exposure of pregnant women between the first to the 20th days of pregnancy reduces the number of viable fetuses per mother (15). However, other studies have produced conflicting results. In pregnant rats exposed to a magnetic field with a frequency of 60 Hz from the 6th to the 20th day of pregnancy showed no significant biological effects in the fetuses and puppies (16). In another study, it was shown that electromagnetic radiation at a frequency of 60 Hz from the 6<sup>th</sup> to the 21<sup>st</sup> day did not have any biological effect on the mother's pregnancy or the first and second generation (17). In a study of pregnant wistar rats that were exposed to a low frequency electromagnetic field, no changes were reported in their body weights or the number of embryos (17). Due to the contradictory results that have been reported, the aim of this study was to evaluate the effect of the exposure to an electromagnetic field during embryonic development, morphological changes in the oocytes, and to affect the differentiation of oocytes and folliculogenesis, resulting in decreased ovarian reserve and leading to infertility or reduced fertility.

## **2. Material and Methods**

### **2-1. Research design**

This research was done experimentally. Thirty rats were taken randomly from laboratory animals, and their ages and weights were determined. Three-month-old rats were selected for testing, and they were divided randomly into three groups, i.e., a control group, experimental group 1, and experimental group 2 with 10 rats in each of the groups. During the experiment, the three groups were maintained and fed in the same conditions. The two experimental groups were exposed to magnetic fields of 50 to 60 Hz, as animals of group 1 received EMF for 8 weeks (three weeks intrauterine + five weeks ectopic) and animals of group 2 received EMF for 13 weeks (three weeks intrauterine + ten weeks ectopic).

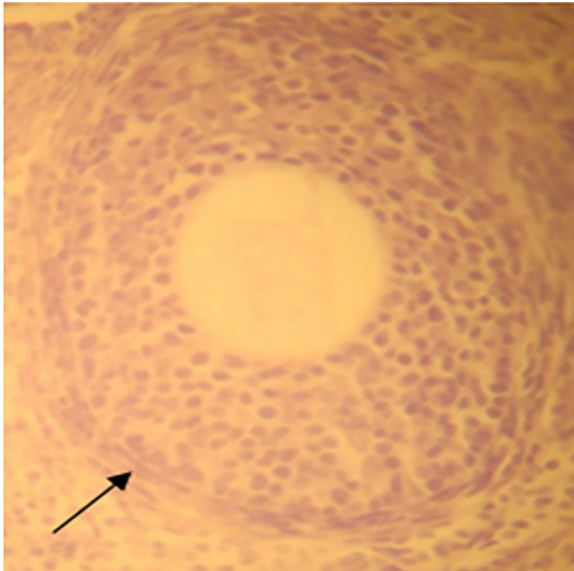
### **2.2. Data Collection**

After the period mentioned above, the rats were anesthetized with pentobarbital (40 mg), and their ovaries and isolated oocytes were removed. The structures in the oocytes' cells were examined, and the cells were fixed immediately in 10% formaldehyde and then embedded in paraffin. Subsequently, the histology process was stained, and the cells were studied using a light microscope. To compare the data obtained from the two groups, 100 microscopic sections were evaluated in each group and atresia of follicles was recorded using a 10X microscopic lens. We used the Kruskal Wallis non-parametric test and SPSS statistical software, version 22.0, to compare the histopathology results.

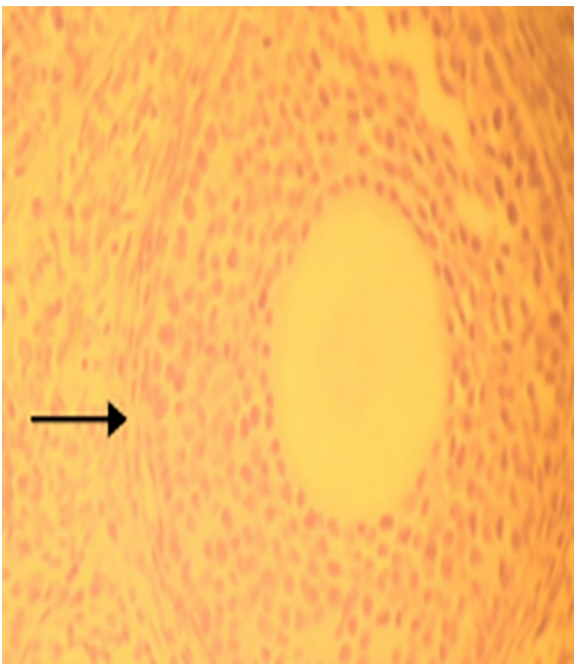
## **3. Results**

Our results indicated that the EMF radiation had harmful effects on the formation of ovarian follicles and ovule implantation. For comparison of results, in each group, 100 microscopic cross-sections were selected and the numbers of follicles with atresia were counted using a 10X microscope lens. For detection of the atresia of the

follicles, we evaluated degenerative changes in the granulosa of the growing primary follicles, the status of cells around the oocytes, and the structure of ovarian stroma. The ovarian follicles showed that the nuclei of the oocytes became smaller and changed in shape. In the groups affected by electromagnetic waves, harmful effects were recorded compared to the control group, and there was a significant difference between the mean numbers of atretic follicles in the control group compare to the experimental groups ( $p < 0.05$ ) (Figures 1, 2).

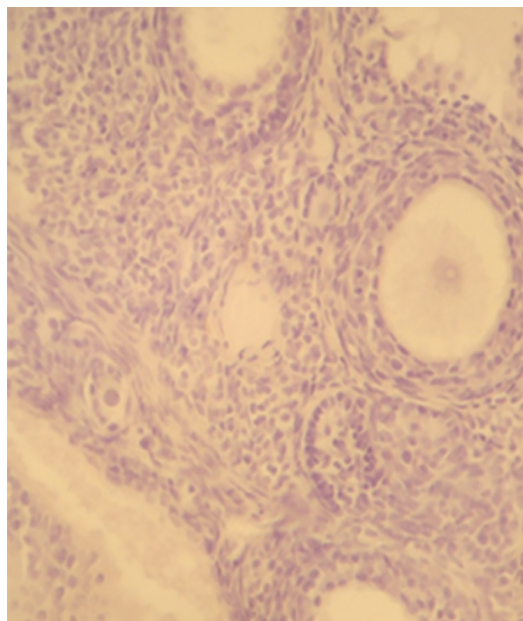


**Figure 1.** Micrograph of light microscope from control group, with growing primary follicles in the bed of the ovarian stroma clearly seen: Granulosa cells around the growing follicles with theca layers are obvious. Zona pellucida with specified thickness in the follicles is evident. 40X Hematoxylin-eosin stains (H & E)

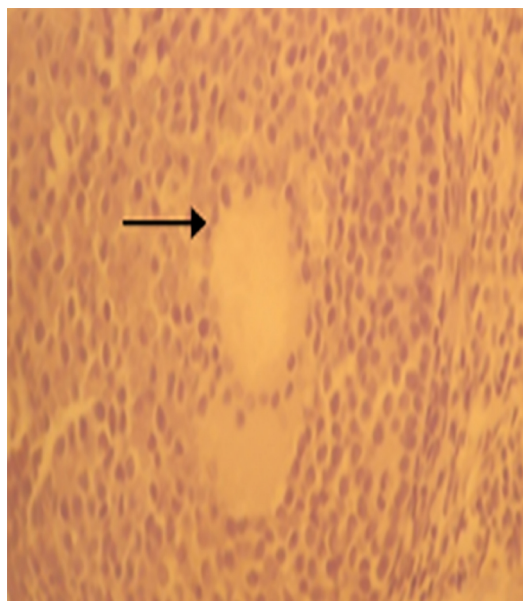


**Figure 2.** Micrograph of light microscope from control group, growing primary follicles with identified granulosa cells that have cores of euchromatin: Zona pellucida layer (Z) around the oocyte has acidophilus color and homogenized and clear. Theca layer (T) on a regular basis is visible around the follicle. 40X Hematoxylin-eosin stains (H & E)

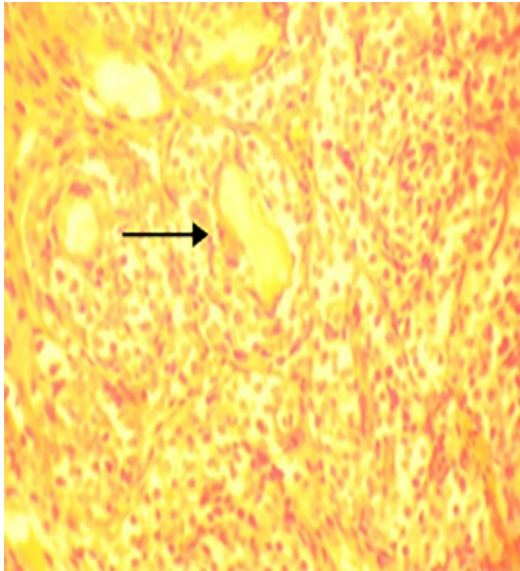
In experimental group 1, growing primary follicles had relatively irregular arrangements with a discrete theca layer and also uneven thickness of the zona pellucida layer in some parts of the follicles (Figures 3, 4). Disappearance and destruction of granulosa of the growing primary follicles were evident in experimental group 2. Irregular oocytes in the follicle were quite evident, and the structure of the ovarian stroma was disrupted. Also, accumulation of collagen fibers in the form of fibrosis was observed in part of the ovarian stroma in experimental group 2 (Figures 5, 6). Our results indicated that the atresia of the ovarian follicles were significantly different in experimental groups 1 and 2 compared to the control group ( $p < 0.05$ ).



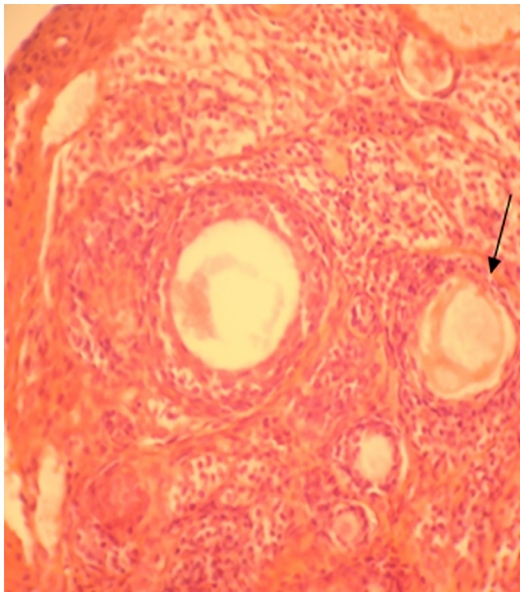
**Figure 3.** Micrograph of light microscope from experimental group(8 weeks), growing ovarian follicles with immature layers of granulosa cells, relatively non-visible Zona pellucida layer with discrete theca layer in stromal bed has seen as it is granular. 40X Hematoxylin-eosin stains (H & E)



**Figure 4.** Micrograph of light microscope from Experimental group (8 weeks), growing primary follicles with relatively irregular arrangement with discrete theca layer and uneven thickness of zona pellucida layer in some parts of the follicles is visible. 40X Hematoxylin-eosin stains (H & E)



**Figure 5.** Micrograph of light microscope from Experimental group (13 weeks), the construction of ovarian stroma turn apart and dilated blood vessels and blood congestion is evident. Also, infiltration of blood leukocytes is visible. 40X Hematoxylin-eosin stains (H & E)



**Figure 6.** Micrograph of light microscope from Experimental group (13 weeks), disappearance and destruction of granulosa of the growing primary follicles were evident: Irregular oocyte in follicle is quite evident (Arrows). Also, the structure of ovarian stroma is disrupted. The oocyte cytoplasm like acidophilus plates within the follicles is visible. Also, accumulation of collagen fibers in the form of fibrosis is seen in part of the ovarian stroma. 40XHematoxylin-eosin stains (H & E)

#### 4. Discussion

The study of the biological effects of electromagnetic fields was considered due to the increasing use of devices that generate electromagnetic waves. The aims were to determine the possible effects of these waves on reproduction, fertility, and embryonic development (18, 19). This study aimed to investigate the effects of electromagnetic field with a frequency of 50 Hz on folliculogenesis and differentiated oocytes of newborn rat pups after pregnancies that were affected by an electromagnetic field. Rats' ovaries during the post-natal period are rich in quiescent and early-growing oocytes that are surrounded by a layer of granulosa cells (20, 21). Exposure to an EMF during embryonic

development can affect folliculogenesis (6) and cause adverse effects on fertility in female mammals (7). In this study, we found that the electromagnetic field can increase the harmful effects on the formation of follicles and ovule implantation. Shrinkage of oocyte nucleoli and the irregular shape of the oocytes also were observed in this study. Maturation, fertilization, and embryonic development before implantation (pre-implantation embryo development) depend on oocyte growth and the differentiation of follicular cells around it (22). Irregular morphology of the core can be a sign of changes in nuclear structure (23). In a study conducted by Bakacak on the effects of an electromagnetic field on ovarian follicles showed that the oocytes' nuclei became smaller and changed in shape (14). Figure 6 shows that the zona pellucida in the follicles was degraded extensively and are no longer visible. Also, leukocytes aggregations for local or topical infiltration were observed around the follicles. Based on the results, exposure to extremely low frequency magnetic fields may impair the fertility of female mammals by reducing the ability of follicles to reach the stage of development that is an essential prerequisite for successful reproduction. The EMF exposure in daily life due to reducing supply of oocytes in the ovaries leads to decrease in infertility (7, 21, 24). It has been shown that follicle atresia in the ovaries is associated with apoptosis of granulosa cells. Programmed death (apoptosis) of ovaries' granulosa cells in the presence of electromagnetic fields has been reported (23). The degeneration of granulosa cells was observed under the influence of the electromagnetic field. Exposures to an EMF during embryonic development affects the process of ovulation, folliculogenesis, loss of egg cells, degeneration of granulosa cells, and decreased ovarian reserve, finally resulting in infertility. Exposure to an EMF during the gestation period can cause alteration in ovarian structures, such as the degeneration of oocytes and follicles. The results of exposure to an EMF were decreased ovarian reserve leading to infertility or reduced fertility.

### 5. Conclusions

According to the findings of this study, it seems that exposure to electromagnetic fields during embryonic development can result in morphological changes in oocytes and differentiation of the oocyte and folliculogenesis, resulting in decreased ovarian reserve leading to infertility or reduced fertility. EMF exposure during the gestation period affects folliculogenesis and ultimately causes infertility. It is recommended that human models be evaluated to gain a better understanding of the other undefined aspects of EMF effects on human reproduction.

### Acknowledgments:

This paper was based on a Ph.D. thesis (No.: 5/77/4031) submitted to Tabriz Health Services Management Research Center. The authors thank the Research Vice-Chancellor of Tabriz University of Medical Sciences for financial support of this study. The authors also thank all family members of the participants and the staff in the Health Centers of the Tabriz District Health Center. This study was approved by the Tabriz Health Services Management Research Center, Tabriz University of Medical Sciences, Tabriz, Iran, on November 22, 2012, with number 5/4/7044.

### Conflict of Interest:

There is no conflict of interest to be declared.

### Authors' contributions:

All authors contributed to this project and article equally. All authors read and approved the final manuscript.

### References

- 1) D'Angelo C, Costantini E, Kamal M, Reale M. Experimental model for ELF-EMF exposure: Concern for human health. *Saudi J Biol Sci.* 2015; 22(1): 75-84. doi: 10.1016/j.sjbs.2014.07.006, PMID: 25561888, PMCID: PMC4281612.
- 2) Hajhosseini L, Khaki A, Merat E, Ainehchi N. Effect of rosmarinic acid on sertoli cells apoptosis and serum antioxidant levels in rats after exposure to electromagnetic fields. *Afr J Tradit Complement Altern Med.* 2013; 10(6): 477-80. PMCID: PMC3847387.
- 3) Ujházy E, Mach M, Navarová J, Brucknerová I, Dubovický M. Teratology—past, present and future. *Interdiscip Toxicol.* 2012; 5(4): 163-8. doi: 10.2478/v10102-012-0027-0, PMID: 23554558.
- 4) Khaki AA, Zarrintan S, Khaki A, Zahedi A. The effects of electromagnetic field on the microstructure of seminal vesicles in rat: a light and transmission electron microscope study. *Pak J Biol Sci.* 2008; 11(5): 692-701. doi: 10.3923/pjbs.2008.692.701, PMID: 18819564.
- 5) Khaki AA, Tubbs R, Shoja M, Rad J, Khaki A, Farahani R, et al. The effects of an electromagnetic field on the boundary tissue of the seminiferous tubules of the rat: A light and transmission electron microscope study. *Folia Morphol.* 2006; 65(3): 188-94. PMID: 16988914.

- 6) Roshangar L, Hamdi B, Khaki A, Rad JS, Soleimani-Rad S. Effect of low-frequency electromagnetic field exposure on oocyte differentiation and follicular development. *Adv Biomed Res.* 2014; 3: 76. doi: 10.4103/2277-9175.125874, PMID: 24627884, PMCID: PMC3950798.
- 7) Cecconi S, Gualtieri G, Di Bartolomeo A, Troiani G, Cifone MG, Canipari R. Evaluation of the effects of extremely low frequency electromagnetic fields on mammalian follicle development. *Hum Reprod.* 2000; 15(11): 2319-25. doi: 10.1093/humrep/15.11.2319, PMID: 11056125.
- 8) Khaki AA, Gharachurlou K, Rad J, Tajik P, Sohrabi I, Khaki A, et al. editors. The effects of electromagnetic field (EMF) on ovary in rat (a light microscopic study). *PLACENTA*; 2008: WB SAUNDERS CO LTD 32 JAMESTOWN RD, LONDON NW1 7BY, ENGLAND.
- 9) Rajaei F, Borhani N, Sabbagh-Ziarani F, Mashayekhi F. Effects of extremely low-frequency electromagnetic field on fertility and heights of epithelial cells in pre-implantation stage endometrium and fallopian tube in mice. *Zhong Xi Yi Jie He Xue Bao.* 2010; 8(1): 56. doi: 10.3736/jcim20100111, PMID: 20082760.
- 10) Cao Y, Zhang Y, Liu Y. [Effects of exposure to extremely low frequency electromagnetic fields on reproduction of female mice and development of offsprings]. *Zhonghua lao dong wei sheng zhi ye bing za zhi.* 2006; 24(8): 468-70. PMID: 16978513.
- 11) de Vocht F, Hannam K, Baker P, Agius R. Maternal residential proximity to sources of extremely low frequency electromagnetic fields and adverse birth outcomes in a UK cohort. *Bioelectromagnetics.* 2014; 35(3): 201-9. doi: 10.1002/bem.21840.
- 12) Wu YL, Ma SR, Peng T, Teng ZH, Liang XY, Guo GZ, et al. Effects of Pulsed Electromagnetic Field on Differentiation of HUES-17 Human Embryonic Stem Cell Line. *Int J Mol Sci.* 2014; 15(8): 14180-90. doi: 10.3390/ijms150814180, PMID: 25196518, PMCID: PMC4159845.
- 13) Hug K, Grize L, Seidler A, Kaatsch P, Schüz J. Parental occupational exposure to extremely low frequency magnetic fields and childhood cancer: a German case-control study. *Am J Epidemiol.* 2010; 171(1): 27-35. doi: 10.1093/aje/kwp339, PMID: 19942577.
- 14) Bakacak M, Bostancı MS, Attar R, Yıldırım ÖK, Yıldırım G, Bakacak Z, et al. The effects of electromagnetic fields on the number of ovarian primordial follicles: An experimental study. *Kaohsiung J Med Sci.* 2015; 31(6): 287-92. doi: 10.1016/j.kjms.2015.03.004, PMID: 26043407.
- 15) Mevissen M, Buntenkötter S, Löscher W. Effects of static and time - varying (50 - Hz) magnetic fields on reproduction and fetal development in rats. *Teratology.* 1994; 50(3): 229-37. doi: 10.1002/tera.1420500308, PMID: 7871487.
- 16) Chung MK, Kim JC, Myung SH, Lee DI. Developmental toxicity evaluation of ELF magnetic fields in Sprague-Dawley rats. *Bioelectromagnetics.* 2003; 24(4): 231-40. doi: 10.1002/bem.10114, PMID: 12696083.
- 17) Chung MK, Kim JC, Myung SH. Lack of adverse effects in pregnant/lactating female rats and their offspring following pre-and postnatal exposure to ELF magnetic fields. *Bioelectromagnetics.* 2004; 25(4): 236-44. doi: 10.1002/bem.10182, PMID: 15114632.
- 18) Portier CJ, Wolfe MS. Assessment of health effects from exposure to power-line frequency electric and magnetic fields. NIH publication. 1998; 98: 3981.
- 19) Huuskonen H, Juutilainen J, Komulainen H. Effects of low - frequency magnetic fields on fetal development in rats. *Bioelectromagnetics.* 1993; 14(3): 205-13. doi: 10.1002/bem.2250140304, PMID: 8323571.
- 20) Da Silva-Buttkus P, Jayasooriya GS, Mora JM, Mobberley M, Ryder TA, Baithun M, et al. Effect of cell shape and packing density on granulosa cell proliferation and formation of multiple layers during early follicle development in the ovary. *J Cell Sci.* 2008; 121(23): 3890-900. doi: 10.1242/jcs.036400.
- 21) Khaki A, Khaki AA, Zahedi A. Effect of *Ocimum basilicum* on Ovary tissue Apoptosis after exposed with extremely low frequency electromagnetic fields (ELF-EMF) in Rats. *Life Sci J.* 2013; 10(3s).
- 22) Klinger FG, De Felici M. In vitro development of growing oocytes from fetal mouse oocytes: stage-specific regulation by stem cell factor and granulosa cells. *Dev Biol.* 2002; 244(1): 85-95. doi: 10.1006/dbio.2002.0592, PMID: 11900461.
- 23) Roushangar L, Rad JS. Ultrastructural alterations and occurrence of apoptosis in developing follicles exposed to low frequency electromagnetic field in rat ovary. *Pak J Biol Sci.* 2007; 10(24): 4413. doi: 10.3923/pjbs.2007.4413.4419, PMID: 19093504.
- 24) Khaki A, Khaki AA. Recovery Effect of Basil on ovarian tissue artery Hyperemia after exposed with electromagnetic field. *Health Med.* 2013; 7(8): 2375.